



Endo-SPONGE®

ENDOLUMINAL VACUUM THERAPY
FOR THE TREATMENT OF ANASTOMOTIC LEAKAGE

Endo-SPONGE®

ENDOLUMINAL VACUUM THERAPY AS A TREATMENT FOR ANASTOMOTIC LEAKAGES IN THE LOW PELVIC AREA

With the introduction of total mesorectal excision (TME) as the standard treatment for rectal carcinoma, the number of low anterior sphincter-preserving rectal resections has increased with a simultaneous decrease in extirpation. One of the most important complication following anterior rectal resection is anastomotic leakage (1, 2).

Clinically manifest anastomotic leakage occurs in up to 24% of patients (3-5).

Because of the immediate proximity of the sphincter to the anastomosis, there is a permanent tailback of infected secretion and gas into the intestinal lumen and into the pelvis.

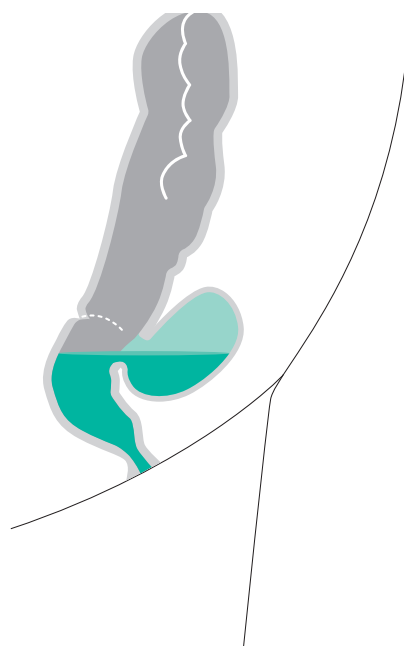
Once an anastomotic leakage has occurred, primary inflammation develops in the area of the anastomosis, localized in the minor pelvis. If the secretion continues to rise, generalized peritonitis can result, with severe septic progression involving multiple organ failure and potentially culminating in the death of the patient (6). Where there is local lower infection of pelvis with an endoscopically accessible cavity, the Endo-SPONGE® treatment can be applied.





ANASTOMOTIC LEAKAGE (AL) IS ONE OF THE MOST IMPORTANT COMPLICATIONS (7, 8):

- AL rate after colorectal surgery is reported to up to 24% (3-5).
- AL is associated to high morbidity and mortality (8, 9).
- AL increases the rates of permanent stomas (8-10).
- AL increase length of hospital stay of patients (11).
- AL increase hospital costs (12).



Endo-SPONGE®

ENDOLUMINAL VACUUM THERAPY FOR THE TREATMENT OF COLORECTAL ANASTOMOTIC
LEAKAGE





SUGGESTED BENEFITS OF VACUUM THERAPY ON THE TISSUE:

- Increase blood flow and edema reduction (13).
- Granulation tissue formation and extracellular synthesis (13).
- Decrease of bacterial contamination and secretion (22).

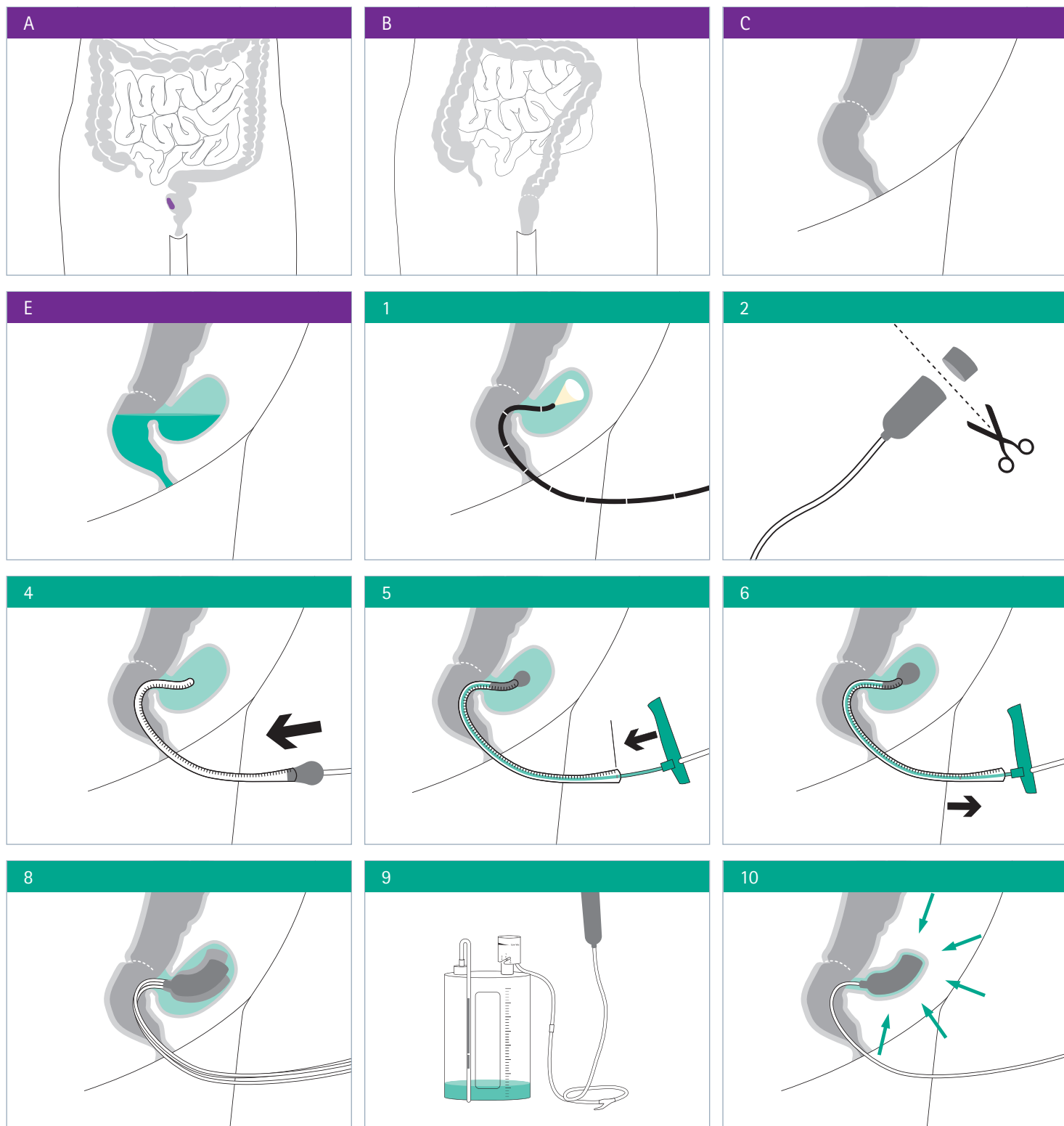
Endo-SPONGE® TREATMENT BENEFITS:

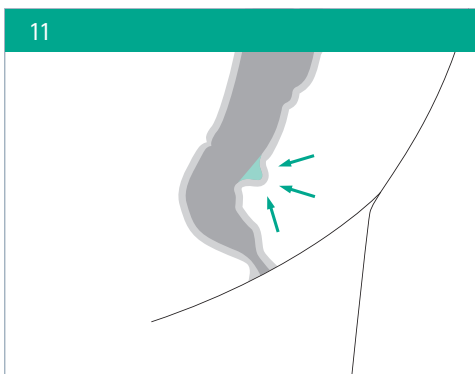
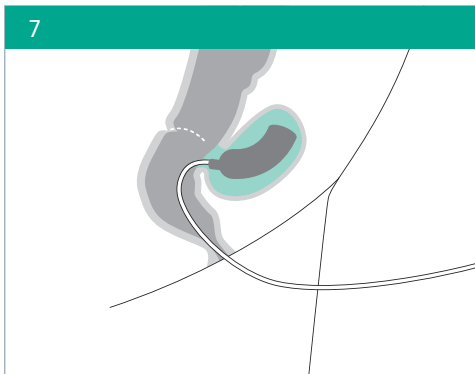
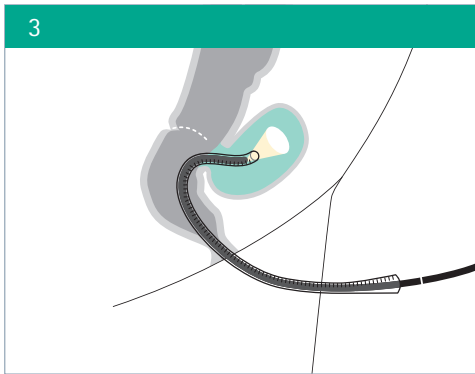
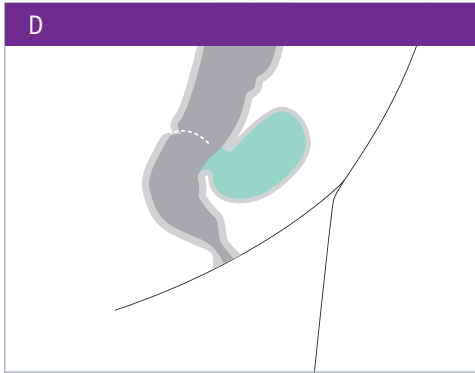- Continuous drainage of the infected wound fluid from the cavity (15).
- Trend to shorter treatment time compared to irrigation (16).
- Treatment median duration is of 20-50 days (15, 17, 20).
- Anastomotic leakage closure is achieved between 67-100% (5, 9, 16-20).
- The treatment works better the sooner it is applied after AL diagnosis (7, 18).
- Ambulatory treatment possible (15, 16, 18-20).
- Good patient acceptance (18-20).
- Reduces hospital stay (8, 18).
- Trend to reduce permanent stomas (increase stomas closure rate) (8, 9).
- There is trend to reduce the number of re-operations (9, 21).
- Could potentially reduce cost of AL treatments (18).

Endo-SPONGE®

ENDOLUMINAL VACUUM THERAPY FOR THE TREATMENT OF COLORECTAL ANASTOMOTIC LEAKAGE

THERAPY PROCEDURE





TREATMENT CRITERIA:

- Localized lower infection of the pelvis.
- Endoscopically accessible leakage.
- Sufficient drainage.

Endo-SPONGE® THERAPY PRINCIPLE:

- The open pores of the sponge allow the suction to be transferred evenly over all tissue in contact with the sponge surface.
- Continuous suction and drainage decrease bacterial contamination, secretion and local edema, promoting perfusion and granulation at the same time (22).

- Fig. A: Tumour in the colorectal area.
- Fig. B: Anastomosis after colorectal surgery.
- Fig. C: Last portion of colon and rectum with an anastomosis.
- Fig. D: In the event of an anastomosis failure a leakage cavity in the colorectal area is created.
- Fig. E: The cavity full of stool creates a localized infection.

Endo-SPONGE® TREATMENT:

- Fig. 1: Asses the cavity with a flexible rectoscope.
- Fig. 2: Cut the sponge to the size of the cavity if necessary.
- Fig. 3: Insert the overtube with the rectoscopy inside, place the overtube at the end of the cavity and withdraw the rectoscope.
- Fig. 4: Push the sponge inside the overtube with the help of the pusher.
- Fig. 5: Use the black mark to control the placement of the sponge at the end of the tube.
- Fig. 6: Keep the sponge in place with the pusher and pull the tube to release it. Remove the overtube and the pusher.
- Fig. 7: The Endo-SPONGE® is placed in the leakage cavity.
- Fig. 8: In case of big cavities up to 3 sponges can be inserted.
- Fig. 9: The Endo-SPONGE® connector tube must be connected to the REDYROB® Trans Plus bottle.
 - Remove the red stopple and plug the two connectors.
 - Select the low vacuum force 1.
- Fig. 10: The vacuum fix the sponge in place and the treatment starts.
- Fig. 11: With the subsequent use of Endo-SPONGE® the cavity is reduced until form a small scar.

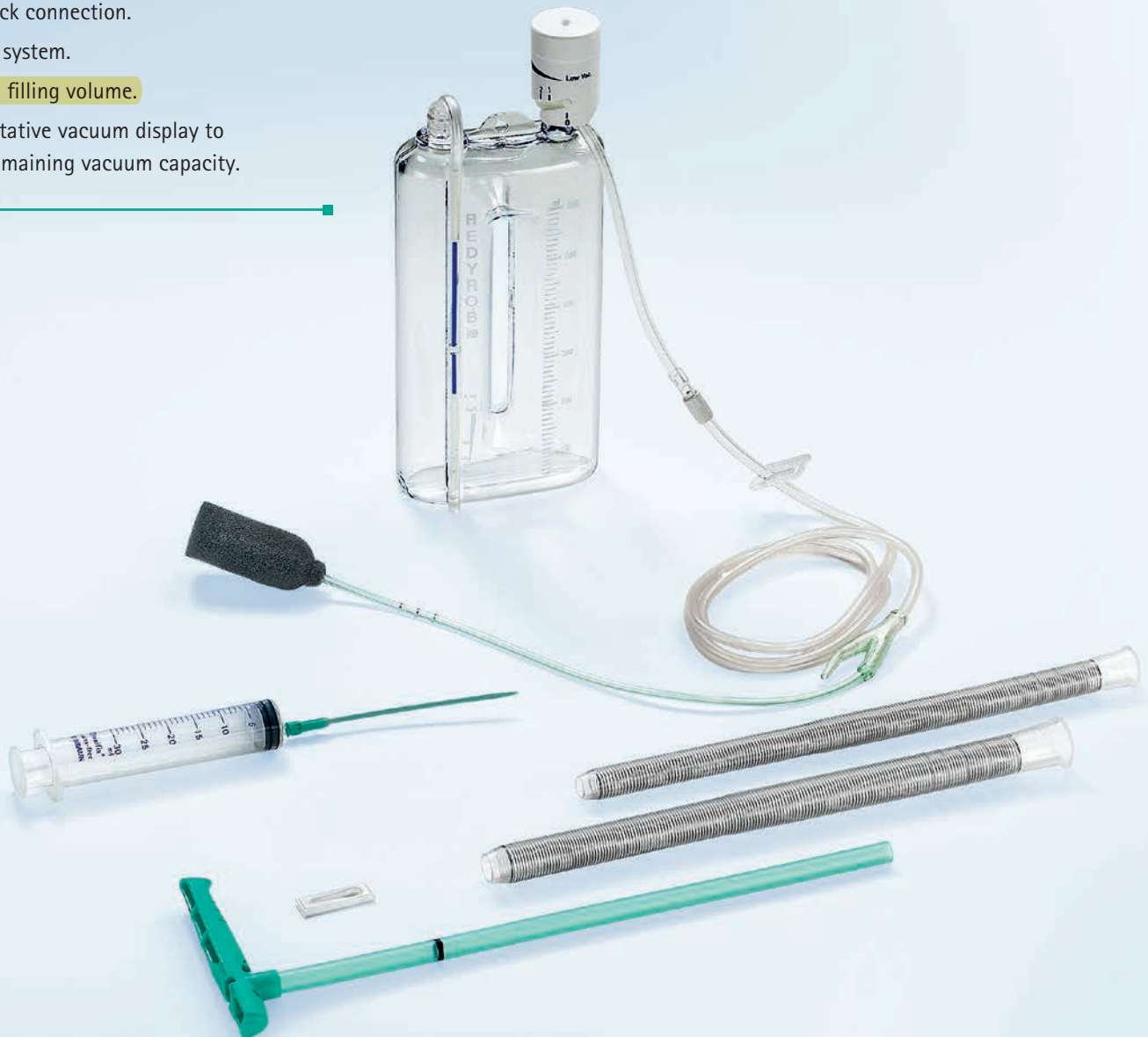Endo-SPONGE®

ENDOLUMINAL VACUUM THERAPY FOR THE TREATMENT OF COLORECTAL ANASTOMOTIC LEAKAGE

ADVANTAGES OF THE REDYROB® TRANS PLUS BOTTLE:

Advantages of the REDYROB® Trans Plus bottle:

- Patient mobility.
- Luer lock connection.
- Closed system.
- 600 ml filling volume.
- Quantitative vacuum display to read remaining vacuum capacity.





QUANTITATIVE VACUUM DISPLAY

High contrast scale gives precise information on the available vacuum capacity.



VACUUM REGULATOR

Positions 1–2–3 for selecting low, medium or high vacuum drainage. Only low vacuum at level 1 has to be used in combination with Endo-SPONGE®.

PRODUCT AND ORDERING INFORMATION



Endo-SPONGE® kit:

- Endo-SPONGE®.
- Overtube in 2 different sizes.
- Pusher.
- Irrigation set.
- Y-shaped connecting tube with Luer lock attachment on REDYROB® Trans Plus bottle.



- **5526510** Box of 10 Endo-SPONGE® kits.
- **5526520** Box of 5 Endo-SPONGE® kits.
- **5526530** Single Endo-SPONGE® kit.

TO BE ORDERED SEPARATELY:

- **5526604** Box of 10 REDYROB® Trans Plus (adjustable wound drainage system).

Endo-SPONGE®

ENDOLUMINAL VACUUM THERAPY FOR THE TREATMENT OF COLORECTAL ANASTOMOTIC LEAKAGE

LITERATURE SUMMARY ON THE USE OF VACUUM THERAPY TO TREAT COLORECTAL ANASTOMOSIS LEAKAGES:

YEAR	PAPER REFERENCE	N	TREATMENT DURATION (DAYS)	NUMBER OF SPONGES
2018	Shalaby et al. (9)	Review of 276 patients	47 (40-105)	7 (3.4-13)
2018	Jimenez-Rodriguez et al. (18)	22	22.3 (7.6-37)	3.1 ± 1.9 LAR/3.2 ± 1.8 Hartmann
2017	Milito et al. (8)	14	35 (16-51)	(3-14)
2016	Kuehn et al. (22)	41	20 (2-131)	6 (1-37)
2015	Keskin et al. (23)	15	na	2.2 (1-5)
2015	Strangio et al. (5)	25	28 (7-128)	9 (1-39)
2015	Gardenbroek et al. (24)	15	12 (7-15)	3 (2-4)
2013	Nerup et al. (16)	13	18 (3-40)	8 (1-18)
2010	Riss et al. (20)	20	21 (7-106)	na
2008	Weidenhagen et al. (15)	29	34 (4-79)	11 (1-27)

THE SUCCESS RATE OF VACUUM THERAPY IS INCREASED WHEN THE TREATMENT IS STARTED EARLY AFTER THE DIAGNOSTIC OF A LEAKAGE:

YEAR	PAPER REFERENCE	N	EARLY TREATMENT (<WEEKS)	RATE OF HEALING EARLY TREATMENT
2009	van Koperen et al. (25)	16	6	6/8 (75%)
2015	Arezzo et al. (19)	14	8.5	9/10 (89%)
2017	Borstlap et al. (7)	30	3	11/15 (73%)

RATE OF HEALING	STOMA CLOSURE
85.3 %	75.9 %
19/22 (86.3 %)	5/13 (38.46 %)
14/14 (100 %)	na
34/41 (83 %)	15/19 (79 %)
12/15 (80 %)	10/14 (71.4 %)
22/25 (88 %)	11/13 (84.6 %)
15/15 (100 %)	14/15 (93.3 %)
13/13 (100 %)	12/13 (92 %)
15/20 (75 %)	13/17 (76.5 %)
28/29 (97 %)	22/25 (88 %)
RATE OF HEALING LATE TREATMENT	
3/8 (56 %)	
2/4 (50 %)	
10/15 (67 %)	

REFERENCES

- (1) Stewart DB, Dietz DW. Total Mesorectal Excision: What Are We Doing? Clin Colon Rectal Surg. 2007;20:190-202.
- (2) Delibegovic S. Introduction to Total Mesorectal Excision. Med Arch. 2017;71(6):434-8.
- (3) Bemelman WA. Vacuum assisted closure in coloproctology. Tech Coloproctol. 2009;13:261-3.
- (4) Srinivasamurthy D, Wood C, Slater R, Garner J. An initial experience using transanal vacuum therapy in pelvic anastomotic leakage. Tech Coloproctol. 2013;17:275-81.
- (5) Strangio G, Zullo A, Ferrara E.C, Anderloni A, Carlino A, Jovani M, Ciscato C, Hassan C, Repici A. Endo-sponge therapy for management of anastomotic leakages after colorectal surgery: A case series and review of the literature. Dig Liver Dis. 2015;47:465-9.
- (6) Phitayakorn R, Delaney CP, Reynolds HL, Champagne BJ, Heriot AG, Neary P, Senagore AJ. Standardized Algorithms for Management of Anastomotic Leaks and Related Abdominal and Pelvic Abscesses After Colorectal Surgery. World J Surg. 2008;32:1147-56.
- (7) Borstlap WAA, Musters GD, Stassen LPS, van Westreenen HL, Hess D, van Dieren S, Festen S, van der Zaag, Tanis PJ, Bemelman WA. Vacuum-assisted early transanal closure of leaking low colorectal anastomoses: the CLEAN study. Surg Endosc. 2018;32(1):315-27.
- (8) Milito G, Lisi G. Endoluminal Vacuum Therapy as treatment for anastomotic colorectal leakage. Surg Technol Int. 2017;10(30):125-30.
- (9) Shalaby M, Emile S, Elfeki H, Sakr A, Wexner SD, Sileri P. Systematic review of endoluminal vacuum-assisted therapy as salvage treatment for rectal anastomotic leakage. BJS open. 2018;3(2):153-60.
- (10) Lindgren R, Hallbook O, Rutegard J, Sjö Dahl R, Matthiessen P. What is the risk for a permanent stoma after low anterior resection of the rectum for cancer? A six-year follow-up of a multicenter trial. Dis Colon Rectum. 2011;54:41-7.
- (11) Blumetti J, Abcarian H. Management of low colorectal anastomotic leak: preserving the anastomosis. World J Gastrointest Surg. 2015;7(12):378-83.
- (12) Ashraf SQ, Burns EM, Jani A, Altman S, Young JD, Cunningham C, Faiz O, Mortensen NJ. The economic impact of anastomotic leakage after anterior resections in English NHS hospitals: are we adequately remunerating them? Colorectal Dis. 2013;15(4):190-8.
- (13) Schintler MV. Negative pressure therapy: theory and practice. Diabetes Metab Res Rev. 2012;28(1):72-7.
- (14) Nagell CF, Holte K. Treatment of anastomotic leakage after rectal resection with transrectal vacuum-assisted drainage (VAC). A method for rapid control of pelvic sepsis and healing. Int J Colorectal Dis. 2006;21(7):657-60.
- (15) Weidenhagen R, Gruetzner KU, Wiecken T, Spelsberg F, Jauch KW. Endoscopic vacuum-assisted closure of anastomotic leakage following anterior resection of the rectum: a new method. Surg Endosc. 2008;22(8):1818-25.
- (16) Nerup N, Johansen JL, Alkhefagie GAA, Maina P, Jensen KH. Promising results after endoscopic vacuum treatment of anastomotic leakage following resection of rectal cancer with ileostomy. Dan Med J. 2013;60(4):A4604.
- (17) Riss S, Stift A, Kienbacher C, Dauser B, Haunold I, Kriwanek S, Radlsboek W, Bergmann M. Recurrent abscess after primary successful endo-sponge treatment of anastomotic leakage following rectal surgery. World J Gastroenterol. 2010;16(36):4570-4.
- (18) Jimenez-Rodriguez RM, Araujo-Miguez A, Sobrino-Rodriguez S, Heller F, Díaz-Pavón JM, Bozada-García JM, de la Portilla F. A new perspective on vacuum-assisted closure for the treatment of anastomotic leak following low anterior resection for rectal cancer, is it worthy? Surg Innov. 2018;25(4):350-6.
- (19) Arezzo A, Verra M, Passera R, Bullano A, Rapetti, Morino M. Long-term efficacy of endoscopic vacuum therapy for the treatment of colorectal anastomotic leaks. Dig Liver Dis. 2015;47(4):342-5.
- (20) Riss S, Stift A, Meier M, Haiden E, Grünberger T, Bergmann M. Endo-Sponge assisted treatment of anastomotic leakage following colorectal surgery. Colorectal Dis. 2010;12(7):104-8.
- (21) Weidenhagen R, Gruetzner KU, Wiecken T, Spelsberg F, Jauch KW. Endoluminal vacuum therapy for the treatment of anastomotic leakage after anterior rectal resection. Rozhl Chir. 2008;87(8):397-402.
- (22) Kuehn F, Janisch F, Schwandner F, Alsfasser G, Schiffmann L, Gock M, Klar E. Endoscopic vacuum therapy in colorectal surgery. J Gastrointest Surg. 2016;20:328-34.
- (23) Keskin M, Bayram O, Bulut T, Balik E. Effectiveness of Endoluminal Vacuum-assisted Closure Therapy (Endosponge) for the Treatment of Pelvic Anastomotic Leakage After Colorectal Surgery. Surg Laparosc Endosc Percutan Tech. 2015;25(6):505-8.
- (24) Gardenbroek TJ, Musters GD, Buskens CJ, Ponsioen CY, D'Haens GR, Dijkgraaf MG, Tanis PJ, Bemelman WA. Early reconstruction of the leaking ileal pouch-anal anastomosis: a novel solution to an old problem. Colorectal Dis. 2015;17(5):426-32.
- (25) van Koperen PJ, van Berge Henegouwen MI, Rosman C, Bakker CM, Heres P, Slors JF, Bemelman WA. The Dutch multicenter experience of the endo-sponge treatment for anastomotic leakage after colorectal surgery. Surg Endosc. 2009;23(6):1379-83.

Distributed by:

B. Braun Surgical, S.A. | Carretera de Terrassa, 121 | 08191 Rubí | Spain
Phone +34 93 586 6200 | Fax +34 93 588 1096 | www.bbraun.com

AESCULAP® – a B. Braun brand

Aesculap AG | Am Aesculap-Platz | 78532 Tuttlingen | Germany
Phone +49 7461 95-0 | Fax +49 7461 95-2600 | www.aesculap.com

Manufacturer acc. to MDD 93/42/EEC

Endo-SPONGE:

B. Braun Surgical, S.A. | Carretera de Terrassa, 121 | 08191 Rubí | Spain

The main product trademark "Aesculap" and the product trademarks "Endo-SPONGE" and "REDYROB" are registered trademarks of B. Braun Melsungen AG and its subsidiaries.

Subject to technical changes. All rights reserved. This brochure may only be used for the exclusive purpose of obtaining information about our products. Reproduction in any form partial or otherwise is not permitted.